



## PAPERS SCAN

Review of “Cartilage Framework Reconstruction  
After Resection of Thyroid Cartilage  
Chondrosarcoma: A Case Report” by  
Navach V, Chu F, Cattaneo A, Zorzi S,  
Scelsi D, Ansarin M in  
*Otolaryngology  
Case Reports*  
2017;4:12–4

This was a well written and creative case report on thyroid cartilage reconstruction (Fig 1) using a novel and simple technique of a free cartilage graft.

As noted by the authors, there is literature to support the benefit of thyroid cartilage reconstruction by reducing incidence of airway collapse and emphysema. I do feel that this is somewhat subjective as there is literature to support unaffected levels of airway and respiratory function with no reconstruction for hemisphere resection of thyroid cartilage. I feel that that literature should also at least be addressed in this paper

to be candid and objective.

I do feel that this method of reconstruction is simple with minimal donor site morbidity, risk of major complications, or markedly increased operative time.

My only criticisms are:

1. That it should address the literature suggesting it may not be needed, as well as the literature stating is of benefit.
2. In cases where a soft tissue envelope is not maintained, a nonvascularized graft would be a poor choice.

In short, well written, useful paper.

Section Editor – Head and Neck Oncological Surgery  
Todd Hanna, MD, DDS, A-FACS  
New York City, NY, USA  
[info@toddhannamdds.com](mailto:info@toddhannamdds.com)



Full Article  
Navach et al

was performed and histopathological findings indicated "low-grade chondrosarcoma".

Computed tomography (CT) results showed a round-shaped lesion arising from the right ala of the thyroid cartilage, with inhomogeneous contrast enhancement surrounded by an incomplete calcified shell, partially dislocating the surrounding structures without signs of infiltration (Fig. 1).

## 2.2. Surgery

The surgical procedure was performed under general anaesthesia with orotracheal intubation. A sterile surgical field was set from the mandibular line, down to the abdomen.

A 6-cm cervical incision was performed at the level of the thyroid cartilage along a natural skin crease of the neck. Sternothyroid and sternohyoid muscles were separated in order to expose the larynx. After cutting the inferior constrictor muscle, the upper and lower horns of the thyroid cartilage were identified and cut, preserving the upper and lower laryngeal nerves, in accordance with the standards of a partial laryngectomy.

The mass was inseparable from the rest of the thyroid cartilage. The laryngeal mucosa was undamaged and gently detached from the neoplasia. The thyroid cartilage was cut at the midline and the neoplasia was safely removed without opening the hypopharynx and larynx. (Fig. 2). The perichondrium was included with the resection.

The ala was reconstructed with a cartilaginous fragment taken from the cartilaginous synchondrosis located between the sixth and eighth rib. During harvesting, we took care to avoid perforating parietal pleura.

The cartilaginous graft was harvested with a synthetic template based on the left residual thyroid ala. It was carved by thinning the internal concave face while the external convex perichondrium was rescued in order to spare graft vascularization.

The graft was placed inside, fixed to the remaining part of the thyroid cartilage along the midline (Fig. 3) with the graft perichondrium facing towards the infra-hyoid muscles to facilitate revascularization of the rib cartilage. A temporary tracheotomy was performed and removed in the fourth day after surgery. No major events occurred during the hospitalization, oral feeding was restored on the second day after surgery and the patient was dismissed after six days. Post-operative laryngeal endoscopy revealed normal laryngeal function and motility with mild ecchymosis of

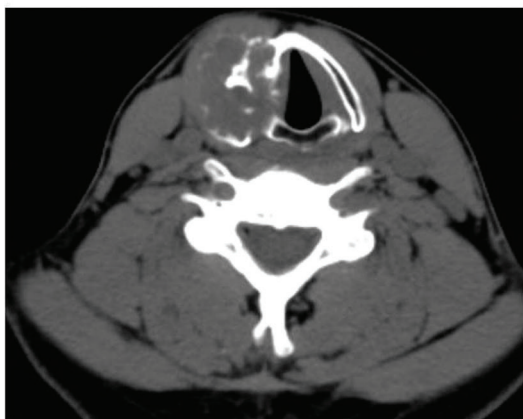


Fig. 1. Preoperative CT scan showing a round shaped, calcified neoplasia of the right ala of the thyroid cartilage.

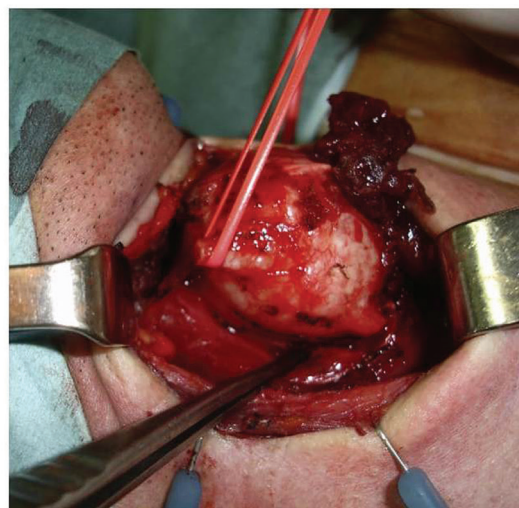


Fig. 2. Intraoperative view: the thyroid ala is cut at the midline and the neoplasia is removed.

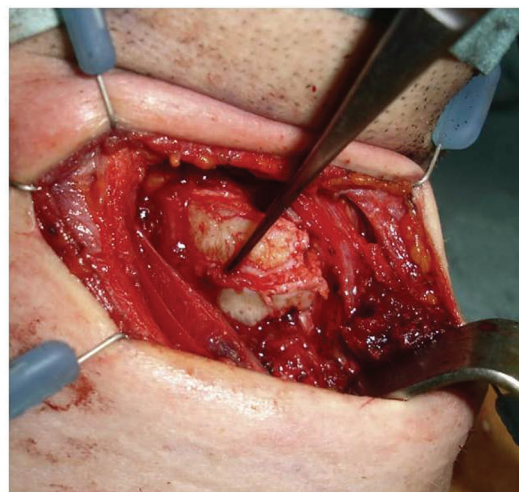


Fig. 3. The cartilage graft replaces the right ala of the thyroid cartilage.

the right hypo-pharyngeal wall. The pathological examination confirmed the diagnosis of low-grade chondrosarcoma, radically excised with safe margins. A CT scan was prescribed at three and six months of follow up, showing no recurrence of disease, the correct inserting of the cartilaginous graft and restoration of its blood supply (Fig. 4). After five years the patient is fully satisfied without evidence of disease.

## 3. Discussion

Chondrosarcomas are a group of heterogeneous tumors that behave very differently depending on the site and the biological characteristics. Low-grade chondrosarcoma has a torpid evolution and good prognosis, while high-grade chondrosarcoma may have a fast negative course [3].